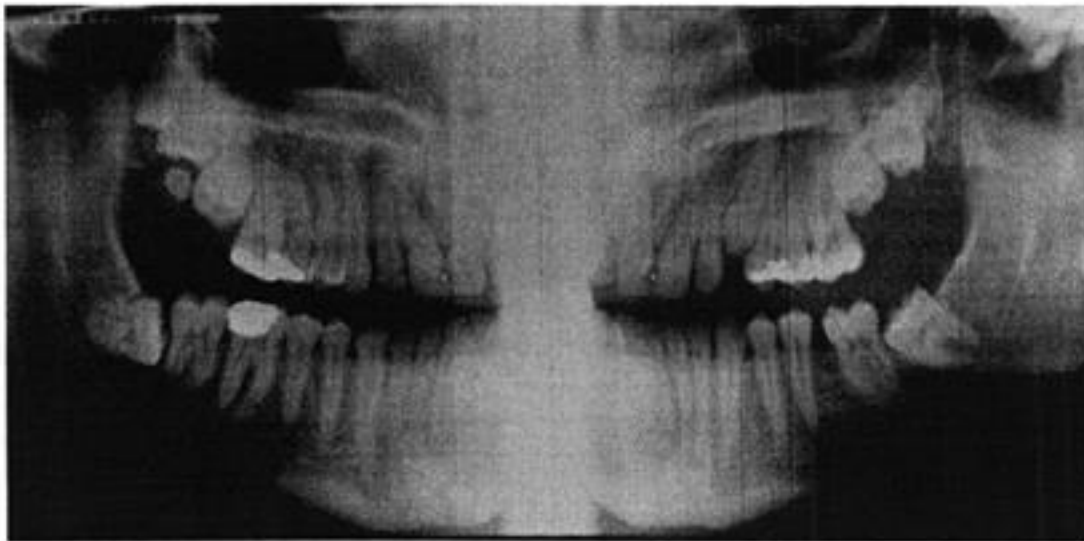


IMPACTED SECOND, THIRD, FOURTH, AND FIFTH MOLARS

A 21-year-old white man came to the Genesee Hospital Emergency Department with a large swelling distal to the upper left first molar. The swelling appeared to completely encircle the second molar, which was not at all visible. The swelling proved to be a lateral periodontal abscess and was subsequently incised and drained. The periapical x-ray film, however, revealed an unerupted second molar and part of a third molar. A second, more distal, periapical x-ray revealed the unerupted third molar and part of an unerupted fourth molar. Finally, a panoramic x-ray revealed, in addition, an unerupted, asymptomatic upper left fifth molar. After the patient declined orthodontic treatment, all nine impacted teeth noted on the panoramic x-ray were removed under general anesthesia. The photograph reveals 90-degree dilacerated roots on the second and third molars and fully formed impacted fourth and fifth molars.

Harvey Levy, D.M.D.
Genesee Hospital
224 Alexander St.
Rochester, N. Y. 14607



ogy,